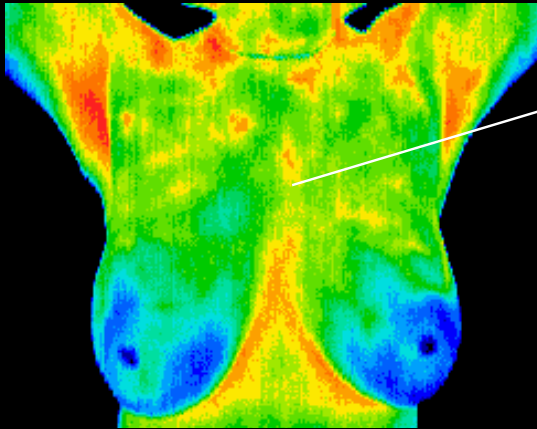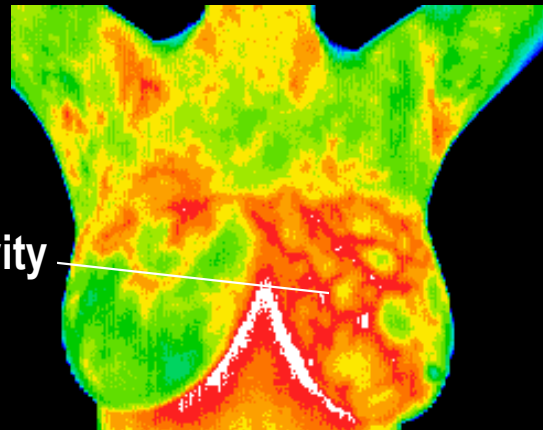
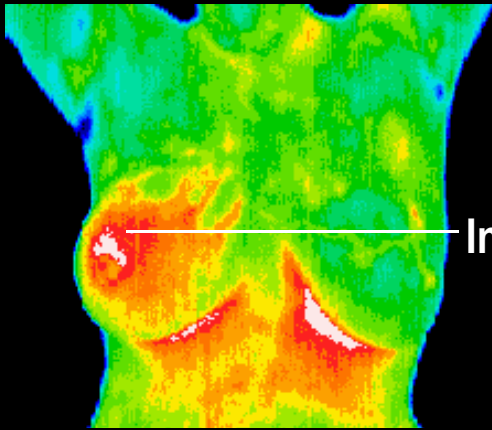


Normal symmetry of healthy breasts

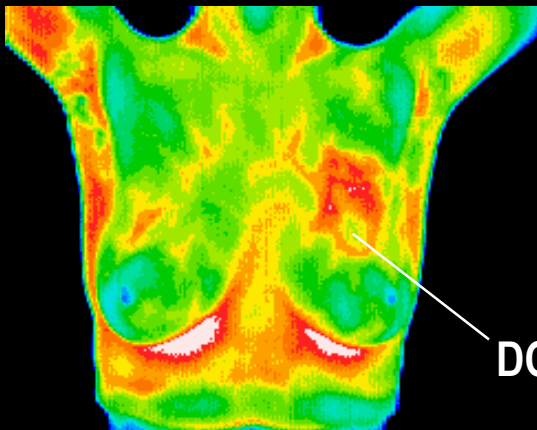
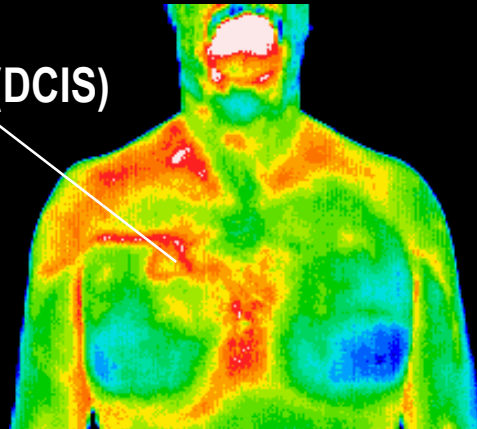


Suspicious vascular activity



Inflammatory breast disease

Male breast cancer (DCIS)



DCIS left breast